

Physics Contribution

ISRS Technical Guidelines for Stereotactic Radiosurgery: Treatment of Small Brain Metastases (≤ 1 cm in Diameter)

Diana Grishchuk, MSc,^{a,*} Alexis Dimitriadis, PhD,^a Arjun Sahgal, MD,^b Antonio De Salles, MD, PhD,^c Laura Fariselli, MD,^d Rupesh Kotecha, MD,^e Marc Levivier, MD, PhD,^f Lijun Ma, PhD,^g Bruce E. Pollock, MD,^h Jean Regis, MD,ⁱ Jason Sheehan, MD, PhD,^j John Suh, MD,^k Shoji Yomo, MD, PhD,^l and Ian Paddick, MSc^a

^aNational Hospital for Neurology and Neurosurgery, London, United Kingdom; ^bDepartment of Radiation Oncology, Sunnybrook Health Sciences Centre, University of Toronto, Ontario, Canada; ^cDepartment of Neurosurgery, University of California, Los Angeles, California; ^dRadiotherapy Unit, Fondazione IRCCS Istituto Neurologico Carlo Besta Milano, Unita di Radioterapia, Milan, Italy; ^eDepartment of Radiation Oncology, Miami Cancer Institute, Baptist Health South Florida, Miami, Florida; ^fNeurosurgery Service and Gamma Knife Center, Center Hospitalier Universitaire Vaudois, Lausanne, Switzerland; ^gDepartment of Radiation Oncology, University of California San Francisco, San Francisco, California; ^hDepartment of Neurologic Surgery, Mayo Clinic, Rochester, Minnesota; ⁱDepartment of Functional Neurosurgery, La Timone Hospital, Aix-Marseille University, Marseille, France; ^jDepartment of Neurologic Surgery, University of Virginia, Charlottesville, Virginia; ^kDepartment of Radiation Oncology, Cleveland Clinic, Cleveland, Ohio; and ^lDivision of Radiation Oncology, Aizawa Comprehensive Cancer Center, Aizawa Hospital, Matsumoto, Japan

Received 2 September 2022; accepted 12 October 2022

Sources of support: This work had no specific funding.

Disclosures: Diana Grishchuk: BrainLAB. Dr Sahgal: Advisor/consultant with Abbvie, Merck, Roche, Varian (Medical Advisory Group), Elekta (Gamma Knife Icon), BrainLAB, and VieCure (medical advisory board); board member International Stereotactic Radiosurgery Society (ISRS); past educational seminars with Elekta AB, Accuray Inc, Varian (CNS teaching faculty), BrainLAB, Medtronic Kyphon; research grant with Elekta AB; travel accommodations/expenses by Elekta, Varian, BrainLAB; belongs to the Elekta MR LINAC Research Consortium, Elekta Spine, Oligometastases and LINAC Based SRS Consortia. Dr Fariselli: ISRS president. Dr Kotecha: Honoraria from Accuray Inc, Elekta AB, ViewRay Inc, Novocure Inc, Peerview Institute for Medical Education, Elsevier Inc, and Brainlab and institutional research funding from Medtronic Inc, Blue Earth Diagnostics Ltd, Novocure Inc, GT Medical Technologies, AstraZeneca, Exelixis, ViewRay Inc, and Brainlab. Dr Regis: Elekta Instrument Research Grant, secretary of the European Society for Stereotactic and Functional Neurosurgery, secretary of the World Society for Stereotactic and Functional Neurosurgery. Dr Suh:

Scientific advisory board member for Novocure, Neutron Therapeutics, and Philips. Ian Paddick: Works as an ad hoc consultant for Elekta; past educational seminars with Elekta AB and Zap Surgical; board member ISRS, serving as past president. All other authors have no disclosures to declare.

Disclaimer and Adherence: These guidelines should not be considered inclusive of all methods of care or exclusive of other methods or care reasonably directed to obtain similar results. The physician must make the ultimate judgment depending on characteristics and circumstances of individual patients. Adherence to this guideline will not ensure successful treatment in every situation. The authors of this guideline and the International Stereotactic Radiosurgery Society assume no liability for the information, conclusions, and recommendations contained in this report.

* Corresponding author: Diana Grishchuk, MSc; E-mail: diana@physicsconsulting.co.uk

<https://doi.org/10.1016/j.prro.2022.10.013>

1879-8500/© 2022 The Author(s). Published by Elsevier Inc. on behalf of American Society for Radiation Oncology. This is an open access article under the CC BY-NC-ND license (<http://creativecommons.org/licenses/by-nc-nd/4.0/>)

Abstract

Purpose: The objective of this literature review was to develop International Stereotactic Radiosurgery Society (ISRS) consensus technical guidelines for the treatment of small, ≤ 1 cm in maximal diameter, intracranial metastases with stereotactic radiosurgery. Although different stereotactic radiosurgery technologies are available, most of them have similar treatment workflows and common technical challenges that are described.

Methods and Materials: A systematic review of the literature published between 2009 and 2020 was performed in Pubmed using the Preferred Reporting Items for Systematic Review and Meta-analyses (PRISMA) methodology. The search terms were limited to those related to radiosurgery of brain metastases and to publications in the English language.

Results: From 484 collected abstract 37 articles were included into the detailed review and bibliographic analysis. An additional 44 papers were identified as relevant from a search of the references. The 81 papers, including additional 7 international guidelines, were deemed relevant to at least one of five areas that were considered paramount for this report. These areas of technical focus have been employed to structure these guidelines: imaging specifications, target volume delineation and localization practices, use of margins, treatment planning techniques, and patient positioning.

Conclusion: This systematic review has demonstrated that Stereotactic Radiosurgery (SRS) for small (1 cm) brain metastases can be safely performed on both Gamma Knife (GK) and CyberKnife (CK) as well as on modern LINACs, specifically tailored for radiosurgical procedures. However, considerable expertise and resources are required for a program based on the latest evidence for best practice.

© 2022 The Author(s). Published by Elsevier Inc. on behalf of American Society for Radiation Oncology. This is an open access article under the CC BY-NC-ND license (<http://creativecommons.org/licenses/by-nc-nd/4.0/>)

Introduction

Brain metastases occur in 10% to 40% of all adult cancers,¹ and they are increasing in incidence as patients with metastatic disease are surviving longer with the use of novel systemic agents, improved imaging techniques, and increased screening of patients at risk of developing subclinical brain metastases. This increase has also resulted in a greater proportion of patients with small and multiple metastases, which can result in technical challenges given that most centers are equipped with modern multileaf collimator (MLC) image guidance based linear accelerators (LINAC) limited by the uncertainties of small field dosimetry and geometry. In addition to the apparatus used, technical challenges in stereotactic radiosurgery (SRS) treatments include imaging, target volume delineation and localization practices, use of margins, treatment planning techniques, and patient positioning.

Recent studies have shown the efficacy of upfront SRS for the treatment of brain metastases,^{2,3} with strong evidence supporting the treatment of patients presenting with up to 4 brain metastases⁴ and increasing evidence supporting its use in patients with multiple metastases (at least up to 10).^{5–8} For patients who have received whole-brain radiation therapy (WBRT), SRS is often used to salvage new or progressive brain metastases, especially in those with radioresistant disease.⁹ However, the practice of upfront WBRT is becoming less common because of the risk of cognitive impairment¹⁰ and lack of tumor control.¹¹ Moreover, in some histologies such as melanoma, the increasing use of targeted and immune-modifying agents that penetrate into the central nervous system tissues and evidence suggesting WBRT does not reduce the risk of intracranial relapse¹² have led to questioning the use of WBRT altogether unless it is considered as salvage therapy when SRS cannot be performed.¹³

The purpose of this systematic review was to develop ISRS guidelines specific to technical considerations for SRS to small brain metastases, defined as ≤ 1 cm in maximal diameter.

Methods and Materials

Using the Preferred Reporting Items for Systematic Review and Meta-Analyses (PRISMA) methodology, a systematic review of the literature was performed by searching PubMed for articles published between from 2009 and 2020. The search was restricted to English language only. A more detailed overview of the search parameters can be found in [Supplementary Material E1](#).

A review of the 484 collected abstracts plus their bibliographic analysis was performed to screen for additional publications, followed by a more detailed review of 37 articles that were deemed relevant for these guidelines. An additional 44 articles were identified in the references of the papers reviewed or from other sources. There were no studies that contained duplicated (related to the same patients) clinical data. Well-known international publications and guidelines were added to support some of the statements.

A survey consisting of 10 questions was developed to specifically address areas of controversy related to the treatment of small brain metastases with SRS. Fourteen members of the ISRS guidelines committee completed the survey.

Results

In total, 81 articles met the inclusion and exclusion criteria for this study and review. The details of the PRISMA search are shown in [Fig 1](#). Most articles represented single-institution publications ($n = 57$, 70%), and contributed to

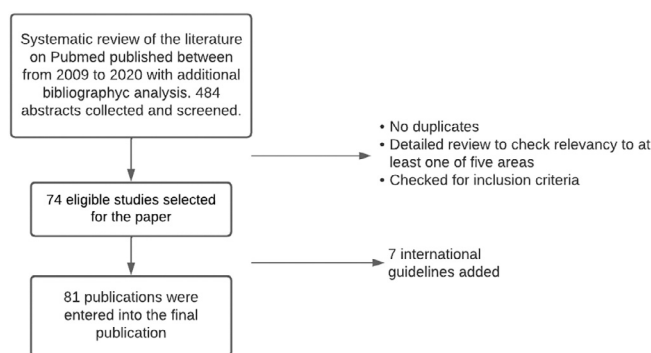


Figure 1 Summary of PRISMA search.

Abbreviation: PRISMA = Preferred Reporting Items for Systematic Reviews and Meta-Analyses.

at least 1 area of the key topics related to the treatment of small brain metastases with SRS, consisting of: imaging ($n = 20$), target volume delineation ($n = 8$), margins ($n = 6$), and technical issues and geometric accuracy ($n = 33$). The greatest proportion of the articles were centered on LINAC-based SRS ($n = 21$) and mixed-platform studies ($n = 21$), followed by Gamma Knife SRS (Elekta AB, Stockholm, Sweden) ($n = 20$), and lastly CyberKnife (Accuray Inc, Sunnyvale, CA) ($n = 2$). The remaining were related to imaging devices and were equally applicable to any SRS platform. Fourteen papers represented technical reports, whereas 9 were retrospective reviews describing clinical outcomes ($n = 7$) or positioning accuracy analyses ($n = 2$). Finally, 7 international guidelines from The American Association of Physicists in Medicine (AAPM), International Atomic Energy Agency, and International Commission on Radiation Units and Measurements (ICRU) were included and evaluated, as they represented substantial bodies of work that have been incorporated into national codes and regulations.

The survey completion rate was 100%. The list of questions can be found in the Supplementary Materials. The survey results are summarized in Table 1 and were rated based on the level of agreement: 80% or more (agree or strongly agree) were ranked as strong consensus, 60% to 79% was ranked as moderate consensus, and less than 60% was ranked as consensus was not reached. A strong consensus for only 5 questions was reached while 3 questions yielded no consensus, which indicates a high variability in current practices.

A brief summary of recommendation by ISRS guidelines committee members for each topic discussed is presented in Table 2.

Discussion

Imaging

Target volume delineation requires 1 or more reference image sets of the intracranial region that contain the

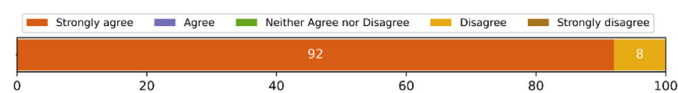target(s) to be treated. Magnetic resonance imaging (MRI) is a prerequisite for the visualization of small metastases, as it is the only modality that can provide the adequate specificity and contrast-to-noise ratio necessary for consistent contouring. An MRI-only treatment planning method can be employed with dose calculation algorithms that assume a uniform water-equivalent density.¹⁴ Contrast-free computed tomography (CT) imaging is necessary to enable a Hounsfield unit to relative electron density conversion in areas of heterogeneous density for convolution-based or Monte Carlo calculation algorithms.¹⁵

Clinically relevant MRI sequences must be optimized for SRS with focus on reducing artifacts and system- and patient-specific geometric distortion.¹⁶ The most commonly used T1-weighted (T1w) sequences for SRS planning of brain metastases are Gradient Echo (for example: Fast Low Angle Shot, Magnetization-Prepared Rapid Acquisition Gradient Echo, Fast Field Echo, Fast Spoiled Gradient Echo, Gradient Recalled Echo, Brain Volume Imaging and Spin Echo (for example: Spin Echo, Sampling Perfection with Application optimised Contrast using different flip angle Evolution). Several studies have been conducted comparing different T1w sequences for the detection of brain metastases.^{17–19,3} Although detectability was higher with certain T1w sequences, the difference did not always reach statistical significance. This, however, changes for scan slice thickness, where fine-cut scans (1–2-mm slice thickness) detected a statistically significant increase of additional small lesions (<1 cm in diameter).^{20,21} The aforementioned studies demonstrate the need for finely tuned sequences for SRS with expert input from neuroradiology and MRI physics.

The improved contrast-to-noise ratio achieved with higher magnetic strength scanners (eg, 3T) have potential benefits in the detection of small brain metastases.²² However, the disadvantage of higher field strengths is increased magnetic susceptibility, which is directly proportional to the static B field. This and other factors can increase geometric distortion in the image, which can potentially lead to positional errors in targeting. An

Table 1 Questionnaire results summary

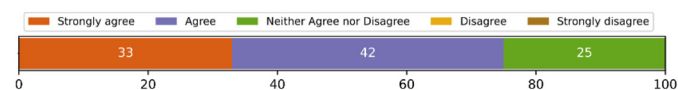
Q1. T1w MRI + Gd with ≤ 1.5 mm slice thickness is required for imaging



Strong consensus reached with

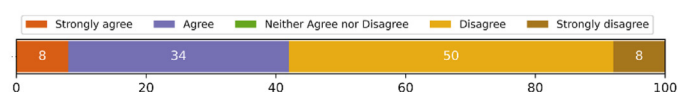
92% who strongly agreed

Q2. Double or triple contrast can detect more or smaller lesions



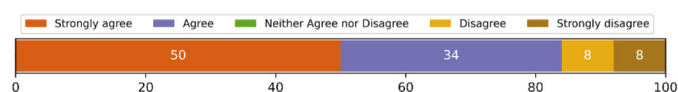
Moderate consensus was
reached with 75% who strongly
agreed or agreed

Q3. A Radiologist should be involved in reviewing the MRI and confirming/validating the detection of ALL small lesions



Consensus not reached

Q4. Target delineation is mandatory in the planning of small metastases (<1 cm diameter)



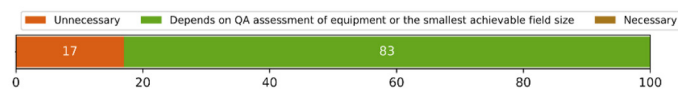Strong consensus was reached
with 84% who strongly agreed
or agreed

Q5. A CTV expansion be added to the GTV in the treatment of small metastases (<1 cm diameter)?



Consensus not reached

Q6. A PTV expansion be used in the treatment of small metastases (<1 cm diameter)?




Strong consensus reached with
83% who agreed that PTV

(Continued)

expansion depends on QA

Q7. The maximum margin that is acceptable to be applied to a small metastasis (<1 cm diameter) is:



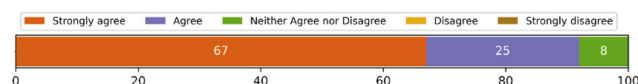Consensus not reached

Q8. Submillimetre geometric accuracy must be achieved for the treatment of small metastases (<1 cm diameter).




Strong consensus reached with
100% who strongly agreed or
agreed

Q9. Dosimetric accuracy within 5% must be achieved for the treatment of small metastases (<1 mm diameter).



Strong consensus reached with
92% who strongly agreed or
agreed

Q10. Small lesions (<1 cm diameter) should be treated even if the patient is receiving concomitantly other types of targeted therapy



Moderate consensus was
reached with 66% who strongly
agreed or agreed

Abbreviations: CTV = clinical target volume; GTV = gross target volume; MRI = magnetic resonance imaging; PTV = planning target volume; QA = quality assurance; T1w = T1-weighted.

important consideration is that the relative effect of geometric distortion on treatment plan dosimetry is highly dependent on target volume, with smaller targets being more prone to this effect.²³

Several on-board distortion correction methods are available from MRI-scanner manufacturers that can be applied to the image acquisition. These corrections, however, do not guarantee improvements in distortion, and

the responsibility lies with the clinical team to evaluate whether these corrected images are clinically appropriate. Studies investigating correction of MRI geometric distortions^{24,25} show that this can be a source of large errors. Regular quality assurance (QA) should be mandatory, using an appropriate phantom to ensure that image quality and geometric distortions are within tolerance. It is important to note that such algorithms do not correct

Table 2 Summary of recommendations

Imaging	<ul style="list-style-type: none"> • Recent MR imaging (≤ 7 days from treatment) is a prerequisite for contouring. • Fine-cut MR scans should be acquired (≤ 1.5-mm slice thickness). • A scan time delay of between 10 and 15 minutes should be applied after contrast injection. • MR sequences should be optimized for SRS to reduce artifacts and geometric distortion. Regular MRI QA is mandatory to monitor geometric distortion as a potential source of error. • CT scans, if used for planning, should be equal to or thinner than MR slice thickness.
Contouring	<ul style="list-style-type: none"> • All targets and OARs should be contoured to quantitatively assess tumor coverage constraints and OAR tolerance levels. • Margins are associated with an increased dose to normal tissue and need to be carefully considered according to the SRS platform.
Patient treatment	<ul style="list-style-type: none"> • Sub-millimeter geometric accuracy must be achieved during treatment. To comply with this requirement the choice of immobilization device and in-room imaging should be made based on the achievable accuracy of patient positioning and target localization. Patient immobilization and localization techniques are critical in this regard. • Lower energy beams may reduce dose to normal tissue.
Dosimetry	<ul style="list-style-type: none"> • Dosimetric accuracy within 5% must be achieved. • Recommendations regarding dosimetrical measurements for small fields have been published by IAEA and AAPM.
<p><i>Abbreviations:</i> AAPM = The American Association of Physicists in Medicine; CT = computed tomography; IAEA = International Atomic Energy Agency; MR = magnetic resonance; OAR = organ at risk; QA = quality assurance; SRS = stereotactic radiosurgery.</p>	

for patient-specific distortions and steps must be taken to prevent or reduce these effects. This is particularly important when planning is solely based on MR images. Coregistration of MRI and CT is 1 common method used to reduce distortion. However, coregistration accuracy should be tested before clinical use.

For LINAC-, CyberKnife, and Gamma Knife Icon based treatments, CT scans (cone beam CT for Gamma Knife Icon) can be used as the reference study for treatment planning and patient positioning. MRI scans serve as the secondary image data sets for volume definition. MRI and CT images are then fused, and the quality of coregistration depends on a variety of factors, including image quality and spatial resolution. The precision of head localization during image-guided positioning also depends on image acquisition settings and, for example, can be improved by a factor of 2 when the slice thickness is reduced from 3.0 to 1.5 mm.²⁶ At present, a CT slice thickness on the order of 1 mm is widely used for SRS treatments to provide sufficient fusion and setup accuracy.

The choice of gadolinium-based contrast agent may also be a significant factor in the MRI visualization of small metastatic disease.²⁷ There is also evidence suggesting that a double or even triple dose of contrast agent is beneficial.²⁸ However, the potential of renal toxicity and long-term gadolinium retention in the brain should be considered to balance the risk versus benefit of improved target visualization.²⁹ The use of the more stable type III gadolinium-based contrast agents should also improve

safety. Equally important is the timing of the scan after contrast injection. Delayed MRI may increase the number, volume size, and conspicuity of metastatic lesions.³⁰ A time delay between 10 and 15 minutes is recommended for optimal tumor definition; however, this has not been universally adopted in clinical practice.

The significant growth rate of brain metastases necessitates recent imaging from treatment planning to SRS delivery. In a retrospective study of 151 brain metastases, the 12-month local freedom from progression after SRS was 95% versus 56% when MRI images used for contouring were <14 and ≥ 14 days from SRS delivery, respectively.³¹ In a more recent study, 531 lesions were evaluated on 2 MRI scans with median interscan time interval of 8 days and demonstrated a median tumor volume growth of 20% for this period.³² The danger of a target changing size and/or shape or the appearance of new lesions between the acquisition of planning images and delivery of treatment should not be ignored. This is particularly important in the treatment of melanoma and renal cell cancers where intratumoural bleeding can often occur spontaneously.³³

Target delineation

The gross tumor volume is a volume defined by ICRU 91 as “very likely to be tumor.”³⁴ In the case of small metastatic lesions, these tend to be spherical or ellipsoid and are most commonly delineated from MRI scans. The

clinical target volume is a volume encompassing the gross tumor volume as an area likely to contain tumor to ensure that any microscopic spread is treated. A clinical target volume margin is not usually applied in the treatment of metastases with SRS, although there is evidence that infiltration into normal brain is present for some metastatic lesions.³⁵ However, the partial volume effect, where an individual voxel appears bright because of the presence of enhancing tumor in only part of its volume, serves to increase the apparent volume of the enhancing target. This can be as much as 1 pixel in radius, which can in effect add or subtract an unintended margin to the target.³⁶ This will depend on the resolution of the image, and a voxel size of $\leq 1 \text{ mm}^3$ will limit this effect.

It has been previously argued that target delineation is the “weakest link” in SRS.^{37,38} This is related to biases from inter- and intraobserver variations,³⁹ variability in treatment planning system (TPS) volume calculation,⁴⁰ and the inconsistent addition/absence of margins. Methods range from automatic segmentation to manual delineation to targets not being contoured at all despite the ICRU recommendation that contouring is a standard of good practice.³⁴

A recent study investigated interobserver contouring variations at 22 SRS centers using a range of benchmarking targets.⁴¹ The case with multiple small metastatic targets showed the largest interobserver variations. Although some of these variations are related to image fusion inaccuracies and TPS volume calculation methods, the authors state that these are also associated with “differences in clinician training, ethos, and accuracy” (p. 20). It was shown that variations decreased with larger target volumes, which is in agreement with another published study.³⁸ Therefore, it is important to recognize that interobserver contouring variations are expected to be exacerbated for metastatic lesions significantly smaller than 1 cm in diameter.

Margins

A planning target volume (PTV) is created by adding a margin to account for possible geometric inaccuracies of the treatment delivery. It is therefore important to assess patient set-up uncertainties, on-board imaging accuracy, movement during treatment, and physical accuracy of the isocenter when considering the margin to be used.³⁴ Equipment limits, including the magnitude of potential geometric errors and baseline parameters for a QA program, should be characterized during commissioning.⁴² Routine end-to-end (E2E) QA tests and, if necessary, pretreatment plan verification should be performed to ensure that the prescription dose can be delivered accurately and to the right spatial location. However, although all treatment techniques are associated with some level of uncertainty in

delivery, a PTV margin is not always applied for SRS treatment, in particular, for rigid-frame based treatment.

In a study investigating target volume and margin growth calculation using different TPS systems,⁴³ volume calculations varied by as much as 10%. The addition of margins (of the same nominal size) to small structures yielded differences up to 40%, resulting in substantially inconsistent total volumes. The authors concluded that these are relatively small variations compared with interobserver discrepancies. However, the addition or omission of a margin remains the biggest and most controversial variable in the treatment of small metastases with SRS. By way of illustration, the volume of a 0.8-cm diameter sphere is 0.268 cc, whereas the volume after the addition of a 1-mm margin is 0.524 cc, which effectively doubles the volume. Assuming the same prescription dose is used for both targets, the dose to normal brain will increase significantly and, in turn, the risk of radiation necrosis will increase as well. This is particularly important when large numbers of lesions in proximity to each other are treated in the same session as a result of dose-interplay effects. In a theoretical study, Ma et al⁴⁰ used Flickinger’s symptomatic radiation necrosis incidence model to examine the effect of adding various margins in Gamma Knife SRS, from 0.5 to 3 mm. Risks increased between 6% and 25% depending on the margin and size of the target. However, in this study, only 1 of 15 of the lesions studied were less than 1-cm diameter. Fortunately, the risk of radionecrosis is relatively low when treating lesions 1 cm in diameter.⁴⁴ In a retrospective study of 2200 treatments performed on a Gamma Knife unit, Sneed et al⁴⁵ reported a 1-year probability of adverse radiation effects of 1% or less when treating lesions up to 1 cm in diameter with a dose of ≤ 20 Gy without a margin. Because the baseline risk for these small targets is low in the model as expected, any substantial increase obtained in the relative risk may not significantly affect the absolute risk for the treatment of these small lesions.

A retrospective clinical study of 93 metastases, treated with or without a 2-mm PTV margin using LINAC-based SRS, revealed a 7.1% and 19.6% risk of severe parenchymal complications, respectively, with no effect on local control.⁴⁶ In a prospective randomized trial, 80 metastases in 49 patients were randomized to a 1- or 3-mm PTV margin and treated with LINAC-based SRS. No difference in local control between the 2 groups was observed; however, an increased incidence in radionecrosis was observed in the 3-mm cohort.⁴⁷ Although in theory the lack of a PTV margin, combined with given random errors in treatment delivery, may suggest a lack of tumor coverage and greater risk of treatment failure, it may be that the penumbral dose results in sufficient control of micrometastatic spread to compensate. Immunologic reactions may also have additive positive effects influencing local control, and this remains an area of research.⁴⁸

Technical issues

SRS planning and treatment techniques are platform dependent. Although traditional intracranial SRS treatment platforms used multi-isocenter or individualized target planning techniques, treatment planning has changed significantly with technological evolution. One recent solution allows for single isocenter, noncoplanar volumetric modulated arc therapy for the treatment of multiple brain metastases.^{49,50} A list of conditions proposed for efficient treatment includes an MLC of 5-mm width or less, on-board imaging combined with a 6-degrees-of-freedom (6-DoF) robotic couch to correct translational and rotation errors, and the possibility to verify patient position at different couch angles for noncoplanar arcs. A 2.5-mm wide MLC might be beneficial for smaller targets, irregular shaped lesions, or those located next to organs-at-risk,⁵¹ but this is balanced by a number of new challenges that include small field dosimetry, beam modeling in the TPS, MLC calibration accuracy, and so forth. Judgment on the superiority of 2.5- versus 5-mm MLC cannot be made based solely on the MLC width parameter. This is also complicated by vendor variations in the recommended technical implementation of smaller leaves. There is a debate in the literature comparing SRS plan qualities depending on leaf width,^{52–56} and the only definitive conclusion we can derive is that an MLC width of no more than 5 mm is a prerequisite for SRS treatments.

Although the majority of intracranial SRS treatments are delivered with energies between ⁶⁰Co and 6 MV, the advent of flattening filter free (FFF) treatments has enabled energies up to 10 MV FFF to be used. A 10 MV FFF beam can offer a higher dose rate but is also associated with a wider penumbra because of the increased lateral scattering of secondary electrons. This effect is aggravated for small fields that increase the proportion of energy scattered outside of the primary photon beam. Laoui et al⁵⁷ studied a series of 93 lesions in 35 patients planned with 6 and 10 MV FFF photon beams. The volume of normal brain irradiated, as defined by the volume within 50% of the prescription isodose line, was 11% lower for the 6 MV FFF beams. This suggests that the 12-Gy volume and the associated risk of radionecrosis may be greater with increasing FFF beam energy.

Geometric accuracy

In 1 study, for lesions ≤ 2 cm in diameter, a prescription dose of 24 Gy was associated with greater local control and less than a 10% risk of radionecrosis.⁵⁸ The dose used in clinical practice for lesions 1 cm in diameter ranges from 18 to 25 Gy,² with further reductions for metastases within or near eloquent regions of the brain. Even though only a small volume receives this high dose

(~ 1 cc), the potential for harm exists, so it is essential for doses of this magnitude to be delivered with a high degree of geometric and dosimetric accuracy.⁵⁹ A geometric miss can damage functional brain tissue and/or undertreat the disease, risking tumor recurrence. As discussed by Schmitt et al,⁵² there are numerous publications and guidelines advising on tolerance levels for an SRS-stereotactic body radiation therapy QA program. A challenge for the clinical team is to establish practical but meaningful tolerance levels for QA results. The authors' consensus is that a geometric tolerance ≤ 1 mm in system-specific E2E tests should be adhered to for treatment of small metastases. However, because of the finite volume irradiated, dosimetric uncertainties may be acceptable in specific clinical scenarios. Readers should refer to the AAPM Task Group Report 142 (TG142),⁶⁰ TG198,⁶¹ and TG178⁶² reports to reference how to assess such uncertainties.

Patient positioning and target localization during treatment are essential to ensure accurate dose delivery. Historically, patients were immobilized using a rigid frame attached to the patient's skull and then fixed to the treatment machine. Isocenters were mechanically secured using the machine and/or frame coordinate system without any in-room image guidance (IG). Although this is still considered the gold standard in SRS, as it ensures sub-millimeter target localization accuracy, it has a number of limitations that include potential frame distortion and slippage,⁶³ patient discomfort, potential cranial complications when fixing the frame near a craniotomy site, inability to perform fractionated SRS without multiple frame applications, and mandatory clinician involvement during frame fixation. As IG is now standard on modern LINAC platforms and more recent Gamma Knife units, in-room imaging guidance can be useful for secondary verifications immediately before the treatment delivery.

In an attempt to allow fractionated treatments to become less invasive and more patient friendly, frameless positioning devices such as bite-block systems and thermoplastic masks have been introduced. These devices removed the need to treat the same day and for a clinician to be involved in preparation. The use of a noninvasive immobilization system requires in-room IG, for example, stereoscopic x-rays or on-board cone beam CT with volumetric image coregistration capability or both. For LINAC-based and CyberKnife radiosurgery, IG is normally accompanied by robotic 6-DoF positional correction, which accounts for both translational and rotational offsets. This system reduces a potential loss of target coverage due to targeting errors.⁶⁴ A 6-DoF couch is especially important for mono-isocentric multiple-target SRS and has been correlated to clinical outcome.⁶⁵ E2E tests have demonstrated that for a single-isocentric noncoplanar arc technique, with cone beam CT and a 6-DoF couch, spatial uncertainty is within 1 mm for targets located within 4 cm of the isocenter and increases to

2 mm beyond this distance.⁶⁵ Therefore, for mono-isocentric techniques, SRS targeting accuracy decreases with increasing distance from the isocenter, and the residual rotational uncertainties remain the primary concern.

Thermoplastic masks are not a new concept in radiation therapy, and are the most common immobilization devices used in the treatment of brain and head and neck patients. However, their suitability for single fraction SRS is controversial. Ohtakara et al⁶⁶ compared positioning accuracy and stability between a dedicated SRS mask system (BrainLab, Munich, Germany) and a general thermoplastic mask system used for conventional radiation therapy using ExacTrac (BrainLab) on-board imaging. The dedicated mask did not have any benefit in initial setup, but post-treatment imaging showed a median vector displacement of 0.38 mm with a maximal translation residual error of 1 mm for the BrainLab mask versus a 0.74 mm median vector displacement with a maximum residual error of 2 mm for the conventional mask. The study concluded that dedicated masks should always be used for treating small targets to minimize intrafraction movement.

Prolonged treatment, which is associated with a greater risk of position shifts and patient stability during mask-based treatment, is another consideration. If there is no real-time monitoring nor adjustments of patient position, time delays between imaging and beam-on delivery should be as short as possible and preferably under 5 minutes to minimize potential targeting errors. For longer time delays, reverification of the patient's position should be considered.⁶⁷ Optical surface IGRT is a viable solution for intrafraction motion tracking. It uses an open-face mask and allows monitoring of intrafraction movements via patient facial topography in real time with an infrared camera, reducing the need for additional x-rays⁶⁸ while improving patient comfort and feelings of claustrophobia. Pham et al⁶⁹ reported that the clinical outcome of SRS treatment with surface IGRT was comparable with conventional frame-based and frameless SRS for brain metastases, but the volume range of lesions as well as the off-center distance of these lesions was not specified in the study. The integration of x-ray imaging and surface IG is evolving in this technology.

The options available for immobilization and localization will depend on the equipment used for treatment. Table 3 shows the reported results for immobilization and on-board imaging combinations. Although there are many commercially available immobilization devices, the level of accuracy required to treat targets less than 1 cm limits options. Before clinical implementation of an SRS service, E2E testing, such as that recommended by the AAPM task group, must be implemented to validate the entire treatment process.⁴² An E2E test aims to reveal problems at any point along the treatment workflow. For such a test, a head phantom encompassing detectors or radiochromic film goes through the entire SRS treatment chain including imaging, contouring, planning, target

localization, and treatment. Geometric and dosimetric differences between the planning system and the delivered dose are then measured and analyzed.

External dosimetry audits before clinical implementation have an important role in ensuring a safe SRS clinical service. A United Kingdom audit assessed dosimetry accuracy achieved in 30 centers across the country.⁵⁹ Variations between calculated and delivered doses for different platforms revealed significant outliers and highlighted the need for standardization of practice. Because the need for external audits was recognized by the study it led to the establishment of an external SRS audit program in the United Kingdom.

Limitations

The most important steps of the SRS workflow, with regards to the treatment of small brain metastases, are covered by these guidelines. However, the topics of SRS service commissioning, QA program development, treatment planning, and delivery techniques that have platform-specific challenges are outside the scope of this paper. National and international dosimetric protocols and technical guidelines should be used to help set up commissioning and QA programs.^{70,71} One example of the latest international document, International Atomic Energy Agency TRS 483, discusses in depth the challenges associated with small-field dosimetry in external beam radiation therapy.

Clinical complications may not manifest themselves over a single SRS session, but with longer survival and additional SRS treatments (in particular as salvage to the same lesion), we should remain concerned about the cumulative dose delivered to the normal brain. This is a complex problem, especially where multiple lesions are treated over multiple sessions with uneven time gaps in between. Such concerns are becoming clinically relevant and warrant further investigation.

Conclusions

We have described the main technological considerations when administering SRS treatments to patients with small (≤ 1 cm) brain metastases. Traditionally, small metastases were treated with SRS only in specialized departments using Gamma Knife, cone-based LINAC systems, and later CyberKnife. At present, there is evidence to show that small metastases can be safely treated with modern LINACs that are appropriately adapted and carefully verified for radiosurgical procedures. This provides an opportunity for treatments at more centers, which is beneficial for global patient care. However, establishing an SRS program should be undertaken with caution as considerable expertise and resources are required.

Table 3 Collation of data from the literature for the accuracy of different platform/positioning/immobilization combinations

Immobilization device	Device characteristics
Gamma Knife Leksell G frame	IGRT: CBCT (starting from Icon model) Patient positioning accuracy: (0.44 ± 0.19) mm (mean \pm SD) – film measurements inside phantom ⁷² (0.48 ± 0.23) mm (mean \pm SD) - film measurements inside phantom ⁷³ Positioning tracking: No Intrafraction motion: Translation: X (0.05 ± 0.04) mm Y (0.03 ± 0.02) mm Z (0.08 ± 0.07) mm Rotation: X $(0.03 \pm 0.03)^\circ$ Y $(0.07 \pm 0.07)^\circ$ Z $(0.07 \pm 0.13)^\circ$ (ref. ⁷⁴) Values relate to: Difference between patient's pre- and post-treatment CBCT
LINAC frame	IGRT: Orthogonal x-rays, CBCT Patient positioning accuracy: (1.0 ± 0.5) mm - orthogonal x-rays (ExacTrac) patient measurements ⁶³ Positioning tracking: No Intrafraction motion: (0.40 ± 0.3) mm - ExacTrac patient measurements ⁶³ (0.30 ± 0.21) mm - ExacTrac patient measurements ⁷⁵ Values relate to: ExacTrac patient measurements
Gamma Knife SRS mask	IGRT: CBCT Patient positioning accuracy: (0.5 ± 0.6) mm ⁷⁶ Positioning tracking: HDMM system (tracking accuracy 0.15 mm) ⁷⁶ Intrafraction motion: (0.62 ± 0.25) mm after correction based on pre-treatment CBCT ⁷⁷ Values relate to: Observed movements during treatment based on HDMM marker position (used a displacement HDMM threshold of 1.5 mm)
Actina PinPoint bite-block system	IGRT: CBCT + 6-DoF robotic couch (HexaPod) Patient positioning accuracy: 6-DoF robotic couch positioning accuracy ± 0.3 mm and $\pm 0.2^\circ$ (ref. ⁷⁶) Positioning tracking: Alarm if vacuum is lost ⁷⁵ Intrafraction motion: (0.45 ± 0.33) mm – difference between pre- and posttreatment patient's CBCT ⁷⁵
Brainlab mask	IGRT: Orthogonal x-rays + 6-DoF robotic couch Patient positioning accuracy: (0.7 ± 0.3) mm – hidden target test ⁶³ Positioning tracking: Infrared optical-tracking system for couch Intrafraction motion: (0.35 ± 0.21) mm – patient's pre- and posttreatment x-ray ⁷⁸ (0.7 ± 0.5) mm – patient's pre- and post-treatment x-ray ⁶³
CyberKnife mask	IGRT: Orthogonal x-rays + 6-joint robotic treatment couch (RoboCouch, Accuray, Inc) ⁷⁹ Positioning tracking: Repeated x-ray image acquisitions at a user-defined frequency (typically every 30-60 s) Intrafraction motion: Translation: X (0.27 ± 0.61) mm Y (0.24 ± 0.62) mm Z (0.14 ± 0.24) mm Rotation: X $(0.13 \pm 0.21)^\circ$ Y $(0.18 \pm 0.25)^\circ$ Z $(0.28 \pm 0.44)^\circ$ (ref. ⁸⁰) Based on patient measurements during treatment with 6D-skull tracking
SGRT open masks	IGRT: CBCT Patient positioning accuracy: Not published Positioning tracking: Tracking 1D accuracy 0.1 ± 0.1 mm ⁸¹

Abbreviations: 6-DoF = 6 degrees of freedom; CBCT = cone beam computed tomography; HDMM = height definition motion management; IGRT = image guided radiation therapy; LINAC = linear accelerator; SD = standard deviation; SGRT = surface IGRT; SRS = stereotactic radiosurgery.

Supplementary materials

Supplementary material associated with this article can be found in the online version at [doi:10.1016/j.prro.2022.10.013](https://doi.org/10.1016/j.prro.2022.10.013).

References

- Muller-Riemenschneider F, Bockelbrink A, Ernst I, et al. Stereotactic radiosurgery for the treatment of brain metastases. *Radiother Oncol*. 2009;91:67-74.
- Lippitz B, Lindquist C, Paddick I, Peterson D, O'Neill K, Beaney R. Stereotactic radiosurgery in the treatment of brain metastases: The current evidence. *Cancer Treat Rev*. 2014;40:48-59.
- Suh CH, Jung SC, Kim KW, Pyo J. The detectability of brain metastases using contrast-enhanced spin-echo or gradient-echo images: A systematic review and meta-analysis. *J Neuro-Oncol*. 2016;129:363-371.
- Sahgal A, Ruschin M, Ma L, Verbakel W, Larson D, Brown PD. Stereotactic radiosurgery alone for multiple brain metastases? A review of clinical and technical issues. *Neuro Oncol*. 2017;19:ii2-ii15.
- Chang WS, Kim HY, Chang JW, Park YG, Chang JH. Analysis of radiosurgical results in patients with brain metastases according to the number of brain lesions: Is stereotactic radiosurgery effective for multiple brain metastases? *J Neurosurg*. 2010;113:73-78. (Special Supplement).

6. Yamamoto M, Serizawa T, Shuto T, et al. Stereotactic radiosurgery for patients with multiple brain metastases (JLKG0901): A multi-institutional prospective observational study. *Lancet Oncol*. 2014;15:387-395.
7. Li J, Ludmir EB, Wang Y, et al. Stereotactic radiosurgery versus whole-brain radiation therapy for patients with 4-15 brain metastases: A phase III randomized controlled trial. *Int J Radiat Oncol Biol Phys*. 2020;108:S21-S22.
8. Milano MT, Chiang VLS, Soltys SG, et al. Executive summary from American Radium Society's appropriate use criteria on neurocognition after stereotactic radiosurgery for multiple brain metastases. *Neuro Oncol*. 2020;22:1728-1741.
9. Hunter GK, Suh JH, Reuther AM, et al. Treatment of five or more brain metastases with stereotactic radiosurgery. *Int J Radiat Oncol Biol Phys*. 2012;83:1394-1398.
10. Chang EL, Wefel JS, Hess KR, Allen PK, Lang FF. Neurocognition in patients with brain metastases treated with radiosurgery or radiosurgery plus whole-brain irradiation: A randomised controlled trial. *Lancet Oncol*. 2009;10:1037-1044.
11. Mulvenna P, Nankivell M, Barton R, et al. Dexamethasone and supportive care with or without whole brain radiotherapy in treating patients with non-small cell lung cancer with brain metastases unsuitable for resection or stereotactic radiotherapy (QUARTZ): Results from a phase 3, non-inferiority. *Lancet*. 2016;388:2004-2014.
12. Hong AM, Fogarty GB, Dolven-Jacobsen K, et al. Adjuvant whole-brain radiation therapy compared with observation after local treatment of melanoma brain metastases: A multicenter, randomized phase III trial. *J Clin Oncol*. 2019;37:3132-3141.
13. Tawbi HA, Forsyth PA, Algazi A, et al. Combined nivolumab and ipilimumab in melanoma metastatic to the brain. *New Engl J Med*. 2018;379:722-730.
14. Rojas-Villabona A, Kitchen N, Paddick I. Investigation of dosimetric differences between the TMR 10 and convolution algorithm for Gamma Knife stereotactic radiosurgery. *J Appl Clin Med Phys*. 2016;17:217-229.
15. Khan FM, Gibbons JP, Sperduto PW. Khan's Treatment Planning in Radiation Oncology, 4th Edition Editor: Faiz M. Khan, John P. Gibbons, Paul W. Sperduto. Lippincott Williams & Wilkins (Wolters Kluwer), Philadelphia, PA, 2016. pp. 648.
16. Sahgal A, Kellett S, Ruschin M, et al. A Cancer Care Ontario organizational guideline for the delivery of stereotactic radiosurgery for brain metastasis in Ontario, Canada. *Pract Radiat Oncol*. 2020;10:243-254.
17. Kakeda S, Korogi Y, Hiai Y, et al. Detection of brain metastasis at 3T: Comparison among SE, IR-FSE and 3D-GRE sequences. *Eur Radiol*. 2007;17:2345-2351.
18. Takeda T, Takeda A, Nagaoka T, et al. Gadolinium-enhanced three-dimensional magnetization-prepared rapid gradient-echo (3D mp-rage) imaging is superior to spin-echo imaging in delineating brain metastases. *Acta Radiol*. 2008;49:1167-1173.
19. Park J, Kim J, Yoo E, Lee H, Chang JH, Kim EY. Detection of small metastatic brain tumors. *Invest Radiol*. 2012;47:136-141.
20. Nagai A, Shibamoto Y, Mori Y, Hashizume C, Hagiwara M, Kobayashi T. Increases in the number of brain metastases detected at frame-fixed, thin-slice MRI for gamma knife surgery planning. *Neuro Oncol*. 2010;12:1187-1192.
21. Hanssens P, Karlsson B, Yeo TT, Chou N, Beute G. Detection of brain micrometastases by high-resolution stereotactic magnetic resonance imaging and its impact on the timing of and risk for distant recurrences. *J Neurosurg*. 2011;115:499-504.
22. Paek SH, Son YD, Chung HT, Kim DG, Cho ZH. Clinical application of 7.0 T magnetic resonance images in gamma knife radiosurgery for a patient with brain metastases. *J Korean Med Sci*. 2011;26:839-843.
23. Paddick I, Kingsley D, Joss R. The QA of CT and MR scans for use with the Gamma Knife. 10th International Meeting of the Leksell Gamma Knife Society. California, USA: Lake Tahoe; April 14-17, 2000.
24. Karaikos P, Moutsatsos A, Pappas E, et al. A simple and efficient methodology to improve geometric accuracy in gamma knife radiation surgery: Implementation in multiple brain metastases. *Int J Radiat Oncol Biol Phys*. 2014;90:1234-1241.
25. Calvo-Ortega JF, Mateos J, Alberich Á, Moragues S, Acebes JJ, Casals J. Evaluation of a novel software application for magnetic resonance distortion correction in cranial stereotactic radiosurgery. *Med Dosim*. 2018;44:136-143.
26. Murphy MJ. Intrafraction geometric uncertainties in frameless image-guided radiosurgery. *Int J Radiat Oncol Biol Phys*. 2009;73:1364-1368.
27. Anzalone N, Essig M, Lee SK, et al. Optimizing contrast-enhanced magnetic resonance imaging characterization of brain metastases: Relevance to stereotactic radiosurgery. *Neurosurgery*. 2013;72:691-701.
28. Kim ES, Chang JH, Choi HS, Kim J, Lee S-K. Diagnostic yield of double-dose gadobutrol in the detection of brain metastasis: Intraindividual comparison with double-dose gadopentetate dimeglumine. *Am J Neuroradiol*. 2010;31:1055-1058.
29. Fraum TJ, Ludwig DR, Bashir MR, Fowler KJ. Gadolinium-based contrast agents: A comprehensive risk assessment. *J Magn Reson Imaging*. 2017;46:338-353.
30. Kushnirsky M, Nguyen V, Katz JS, et al. Time-delayed contrast-enhanced MRI improves detection of brain metastases and apparent treatment volumes. *J Neurosurg*. 2016;124:489-495.
31. Seymour ZA, Fogh SE, Westcott SK, et al. Interval from imaging to treatment delivery in the radiation surgery age: How long is too long? *Int J Radiat Oncol Biol Phys*. 2015;93:126-132.
32. Kutuk T, Tolakanahalli R, Williams A, et al. Neuro-oncology practice displacement for brain metastases undergoing stereotactic radiosurgery. *Neuro-Oncol Pract*. 2021;8:674-683.
33. Destian S, Sze G, Krol G, Zimmerman RD, Deck MD. MR imaging of hemorrhagic intracranial neoplasms. *Am J Roentgenol*. 1989;152:137-144.
34. Wilke L, Andratschke N, Blanck O, et al. ICRU report 91 on prescribing, recording, and reporting of stereotactic treatments with small photon beams. *Strahlenther Onkol*. 2019;195:193-198.
35. Baumert BG, Rutten I, Dehing-Oberije C, et al. A pathology-based substrate for target definition in radiosurgery of brain metastases. *Int J Radiat Oncol Biol Phys*. 2006;66:187-194.
36. Tohka J. Partial volume effect modeling for segmentation and tissue classification of brain magnetic resonance images: A review. *World J Radiol*. 2014;6:855-864.
37. Njeh C. Tumor delineation: The weakest link in the search for accuracy in radiotherapy. *J Med Phys*. 2008;33:136-140.
38. Sandström H, Jokura H, Chung C, Toma-Dasu I. Multi-institutional study of the variability in target delineation for six targets commonly treated with radiosurgery. *Acta Oncol*. 2018;57:1515-1520.
39. Stanley J, Dunscombe P, Lau H, et al. The effect of contouring variability on dosimetric parameters for brain metastases treated with stereotactic radiosurgery. *Int J Radiat Oncol Biol Phys*. 2013;87:924-931.
40. Ma L, Sahgal A, Larson D, et al. Impact of millimeter-level margins on peripheral normal brain sparing for Gamma Knife radiosurgery. *Int J Radiat Oncol Biol Phys*. 2014;89:206-213.
41. Growcott S, Dembrey T, Patel R, Eaton D, Cameron A. Inter-observer variability in target volume delineations of benign and metastatic brain tumours for stereotactic radiosurgery: Results of a national quality assurance programme. *Clin Oncol (R Coll Radiol)*. 2020;32:13-25.
42. Halvorsen PH, Cirino E, Das JJ, et al. AAPM-RSS medical physics practice guideline 9.a. for SRS-SBRT. *J Appl Clin Med Phys*. 2017;18:10-21.
43. Eaton DJ, Alty K. Dependence of volume calculation and margin growth accuracy on treatment planning systems for stereotactic radiosurgery. *Brit J Radiol*. 2017;90: 20170633.
44. Kohutek ZA, Yamada Y, Chan TA, et al. Long-term risk of radionecrosis and imaging changes after stereotactic radiosurgery for brain metastases. *J Neuro-Oncol*. 2015;125:149-156.

45. Sneed PK, Mendez J, Vemer-van den Hoek JGM, et al. Adverse radiation effect after stereotactic radiosurgery for brain metastases: Incidence, time course, and risk factors. *J Neurosurg.* 2015;123:373-386.
46. Nataf F, Schlienger M, Liu Z, et al. Radiosurgery with or without a 2-mm margin for 93 single brain metastases. *Int J Radiat Oncol Biol Phys.* 2008;70:766-772.
47. Kirkpatrick JP, Wang Z, Sampson J, et al. Defining the optimal planning target volume in image-guided stereotactic radiosurgery of brain metastases: Results of a randomized trial. *Int J Radiat Oncol Biol Phys.* 2015;91:100-108.
48. Lehrer EJ, McGee HM, Peterson JL, et al. Stereotactic radiosurgery and immune checkpoint inhibitors in the management of brain metastases. *Int J Mol Sci.* 2018;19:1-18.
49. Hartgerink D, Swinnen A, Roberge D, et al. LINAC based stereotactic radiosurgery for multiple brain metastases: guidance for clinical implementation. *Acta Oncol.* 2019;58:1275-1282.
50. Audet C, Poffenbarger BA, Chang P, et al. Evaluation of volumetric modulated arc therapy for cranial radiosurgery using multiple non-coplanar arcs. *Med Phys.* 2011;38:5863-5872.
51. Tanyi JA, Kato CM, Chen Y, Chen Z, Fuss M. Impact of the high-definition multileaf collimator on linear accelerator-based intracranial stereotactic radiosurgery. *Brit J Radiol.* 2011;84:629-638.
52. Schmitt D, Blanck O, Gauer T, et al. Technological quality requirements for stereotactic radiotherapy: Expert review group consensus from the DGMP Working Group for Physics and Technology in Stereotactic Radiotherapy. *Strahlenther Onkol.* 2020;196:421-443.
53. Chae SM, Lee KW, Son SH. Dosimetric impact of multileaf collimator leaf width according to sophisticated grade of technique in the IMRT and VMAT planning for pituitary adenoma lesion. *Oncotarget.* 2016;7:78119-78126.
54. Hossain S, Keeling V, Ahmad S, Algan O SU-E-T-331: Dosimetric impact of multileaf collimator leaf width on stereotactic radiosurgery (SRS) RapidArc treatment plans for single and multiple brain metastases. *Med Phys.* 2015;42:3409.
55. Padmanaban S, Tunstall C, Buckle A, et al. EP-1981 Clinical delivery of stereotactic radiosurgery using a linac with 5mm MLC. *Radiother Oncol.* 2018;127(Suppl 1):S1-S1291.
56. Burghlea M, Verellen D, Gevaert T, et al. Feasibility of using the Vero SBRT system for intracranial SRS. *J Appl Clin Med Phys.* 2014;15:4437.
57. Laoui S, Roa D E, Kuo J, et al. Flattening filter free beam energy selection and its impact in multitarget intracranial stereotactic radiosurgery treatments. *Med Dosim.* 2020;45:363-367.
58. Mohammadi A M, Schroeder J L, Angelov L, et al. Impact of the radiosurgery prescription dose on the local control of small (2 cm or smaller) brain metastases. *J Neurosurg.* 2016;126:735-743.
59. Dimitriadis A, Tsang Y, Thomas R A S, et al. Multi-institutional dosimetric delivery assessment of intracranial stereotactic radiosurgery on different treatment platforms. *Radiother Oncol.* 2020;147:153-161.
60. Klein EE, Hanley J, Bayouth J, et al. Task group 142 report: Quality assurance of medical accelerators. *Med Phys.* 2009;36:4197-4212.
61. Hanley J, Dresser S, William S, et al. AAPM Task Group 198 Report: An implementation guide for TG 142 quality assurance of medical accelerators. *Med Phys.* 2021;48:e830-e885.
62. Petti PL, Rivard MJ, Alvarez PE, et al. Recommendations on the practice of calibration, dosimetry, and quality assurance for gamma stereotactic radiosurgery: Report of AAPM Task Group 178. *Med Phys.* 2021;48:e733-e770.
63. Ramakrishna N, Rosca F, Friesen S, Tezcanli E, Zygmanski P, Hacker F. A clinical comparison of patient setup and intra-fraction motion using frame-based radiosurgery versus a frameless image-guided radiosurgery system for intracranial lesions. *Radiother Oncol.* 2010;95:109-115.
64. Gevaert T, Verellen D, Engels B, et al. Clinical evaluation of a robotic 6-degree of freedom treatment couch for frameless radiosurgery. *Int J Radiat Oncol.* 2012;83:467-474.
65. Saenz DL, Li Y, Rasmussen K, Stathakis S, Pappas E, Papanikolaou N. Dosimetric and localization accuracy of Elekta high definition dynamic radiosurgery. *Phys Medica.* 2018;54:146-151.
66. Ohtakara K, Hayashi S, Tanaka H, et al. Clinical comparison of positional accuracy and stability between dedicated versus conventional masks for immobilization in cranial stereotactic radiotherapy using 6-degree-of-freedom image guidance system-integrated platform. *Radiother Oncol.* 2012;102:198-205.
67. Tarnavski N, Engelholm S A, Rosenschold P M. Fast intra-fractional image-guidance with 6D positioning correction reduces delivery uncertainty for stereotactic radiosurgery and radiotherapy. *J Radiosurg SBRT.* 2015;4:15-20.
68. Lau S, Patel K, Kim T, et al. Clinical efficacy and safety of surface imaging guided radiosurgery (SIG-RS) in the treatment of benign skull base tumors. *J Neuro-Oncol.* 2017;132:307-312.
69. Pham NLL, Reddy Pv, Murphy JD, et al. Frameless, real-time, surface imaging-guided radiosurgery: Update on clinical outcomes for brain metastases. *Transl Cancer Res.* 2014;3:351-357.
70. Weintraub S. International Atomic Energy Agency. *Nature.* 1965;207:1138.
71. Das IJ, Francescon P, Moran JM, et al. Report of AAPM Task Group 155: Megavoltage photon beam dosimetry in small fields and non-equilibrium conditions. *Med Phys.* 2021;48:e886-e921.
72. Heck B, Jess-Hempfen A, Kreiner HJ, Schöpgens H, Mack A. Accuracy and stability of positioning in radiosurgery: Long term results of the Gamma Knife system. *Med Phys.* 2007;34:1487-1495.
73. Mack A, Czempel H, Kreiner HJ, Durr G, Wowra B. Quality assurance in stereotactic space. A system test for verifying the accuracy of aim in radiosurgery. *Med Phys.* 2002;29:561-568.
74. Carminucci A, Nie K, Weiner J, Hargreaves E, Danish SF. Assessment of motion error for frame-based and noninvasive mask-based fixation using the Leksell Gamma Knife Icon radiosurgery system. *J Neurosurg.* 2018;129:133-139.
75. Babic S, Lee Y, Ruschin M, et al. To frame or not to frame? Cone-beam CT-based analysis of head immobilization devices specific to linac-based stereotactic radiosurgery and radiotherapy. *J Appl Clin Med Phys.* 2018;19:111-120.
76. Chung HT, Park WY, Kim TH, Kim YK, Chun KJ. Assessment of the accuracy and stability of frameless gamma knife radiosurgery. *J Appl Clin Med Phys.* 2018;19:148-154.
77. MacDonald RL, Lee Y, Schasfoort J, Soliman H, Sahgal A, Ruschin M. Real-time infrared motion tracking analysis for patients treated with gated frameless image guided stereotactic radiosurgery. *Int J Radiat Oncol.* 2020;106:413-421.
78. Verbakel WFA, Lagerwaard FJ, Verduin AJE, Heukelom S, Slotman BJ, Cuijpers JP. The accuracy of frameless stereotactic intracranial radiosurgery. *Radiother Oncol.* 2010;97:390-394.
79. Pantelis E, Moutsatsos A, Antypas C, et al. On the total system error of a robotic radiosurgery system: Phantom measurements, clinical evaluation and long-term analysis. *Phys Med Biol.* 2018;63: 165015.
80. Tejinder K, Kushal N, Gupta D, et al. Analysis of intrafraction motion in CyberKnife - based stereotaxy using mask based immobilization and 6D-skull tracking. *J Radiosurg SBRT.* 2016;4:203-212.
81. Li G, Ballangrud A, Kuo LC, Kang H, Kirov A, Lovelock M. Motion monitoring for cranial frameless stereotactic radiosurgery using video-based three-dimensional optical surface imaging. *Med Phys.* 2011;38:3981-3994.